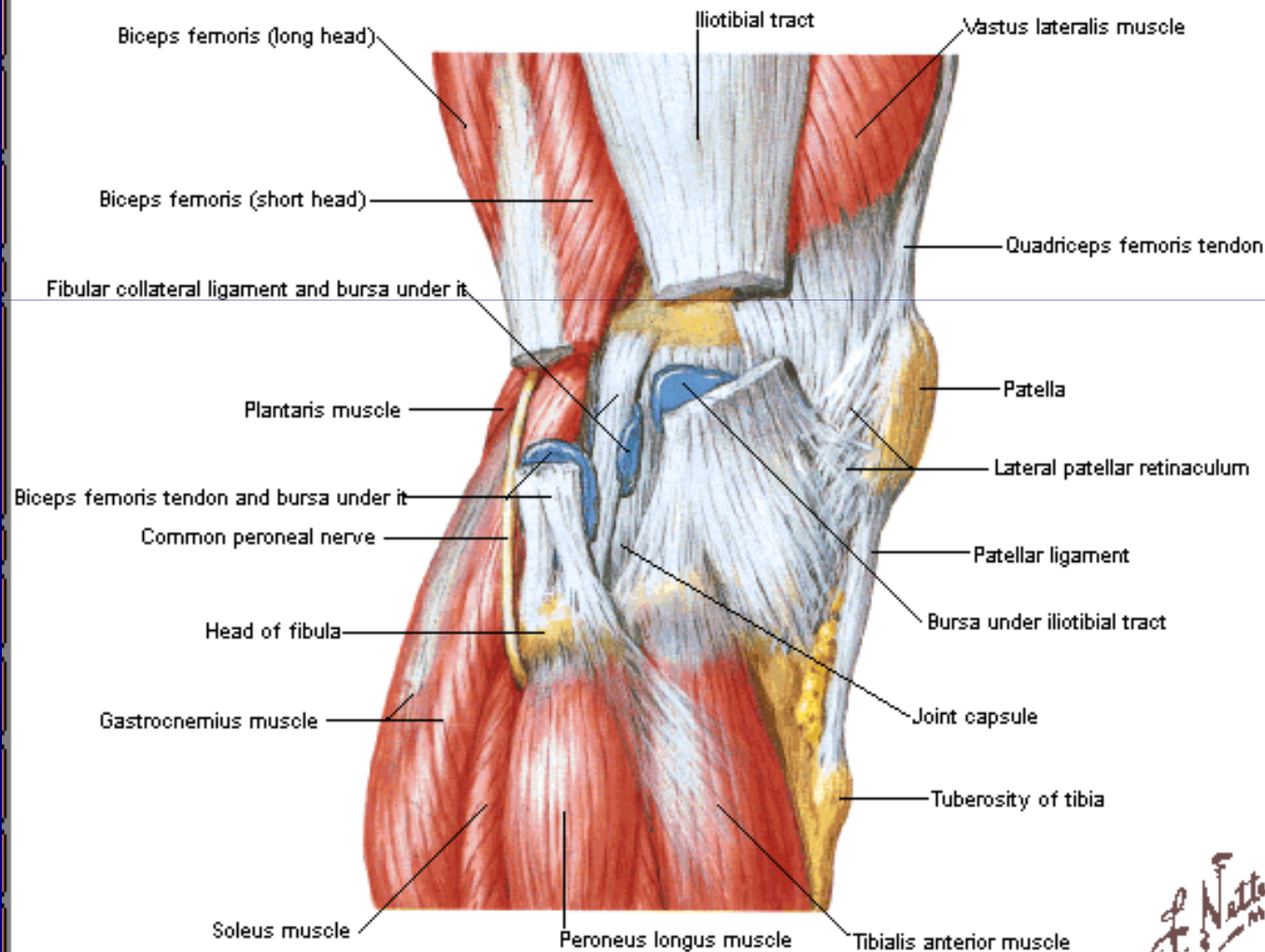


ANATOMIA, BIOMECANICA E SEMIOLOGIA DO JOELHO

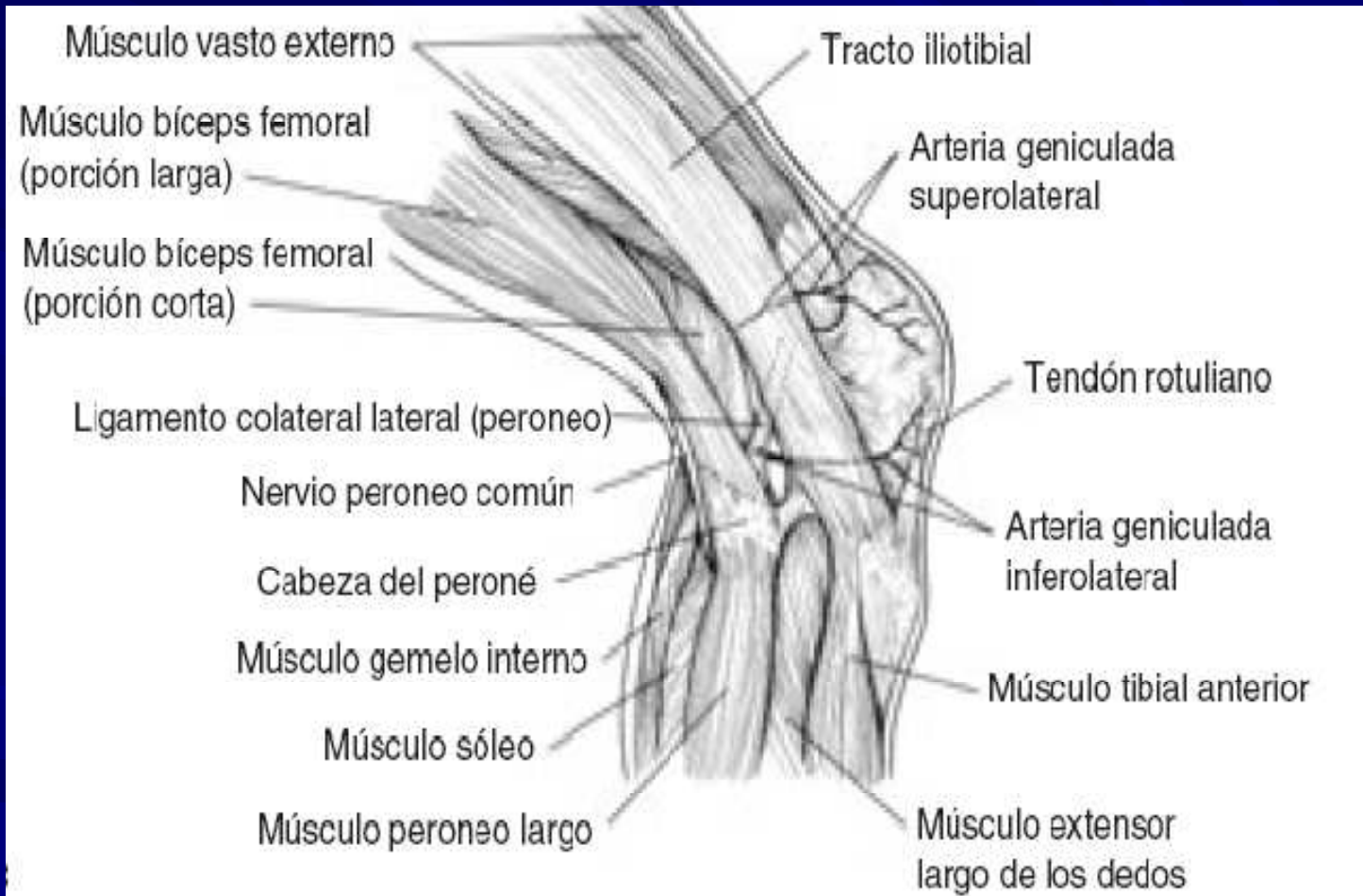
Ricardo Yabumoto

ANATOMIA

Knee Lateral View

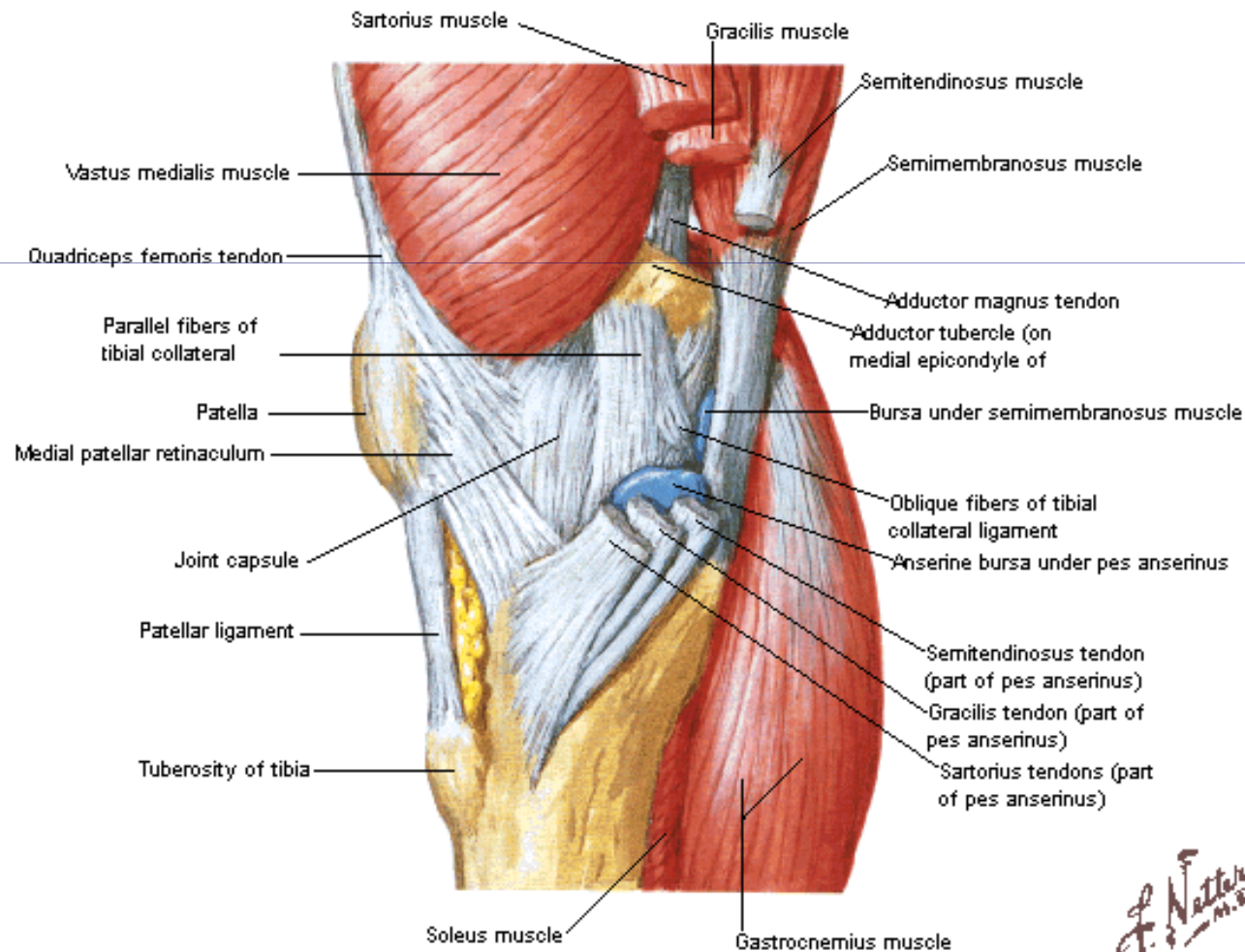


ANATOMIA



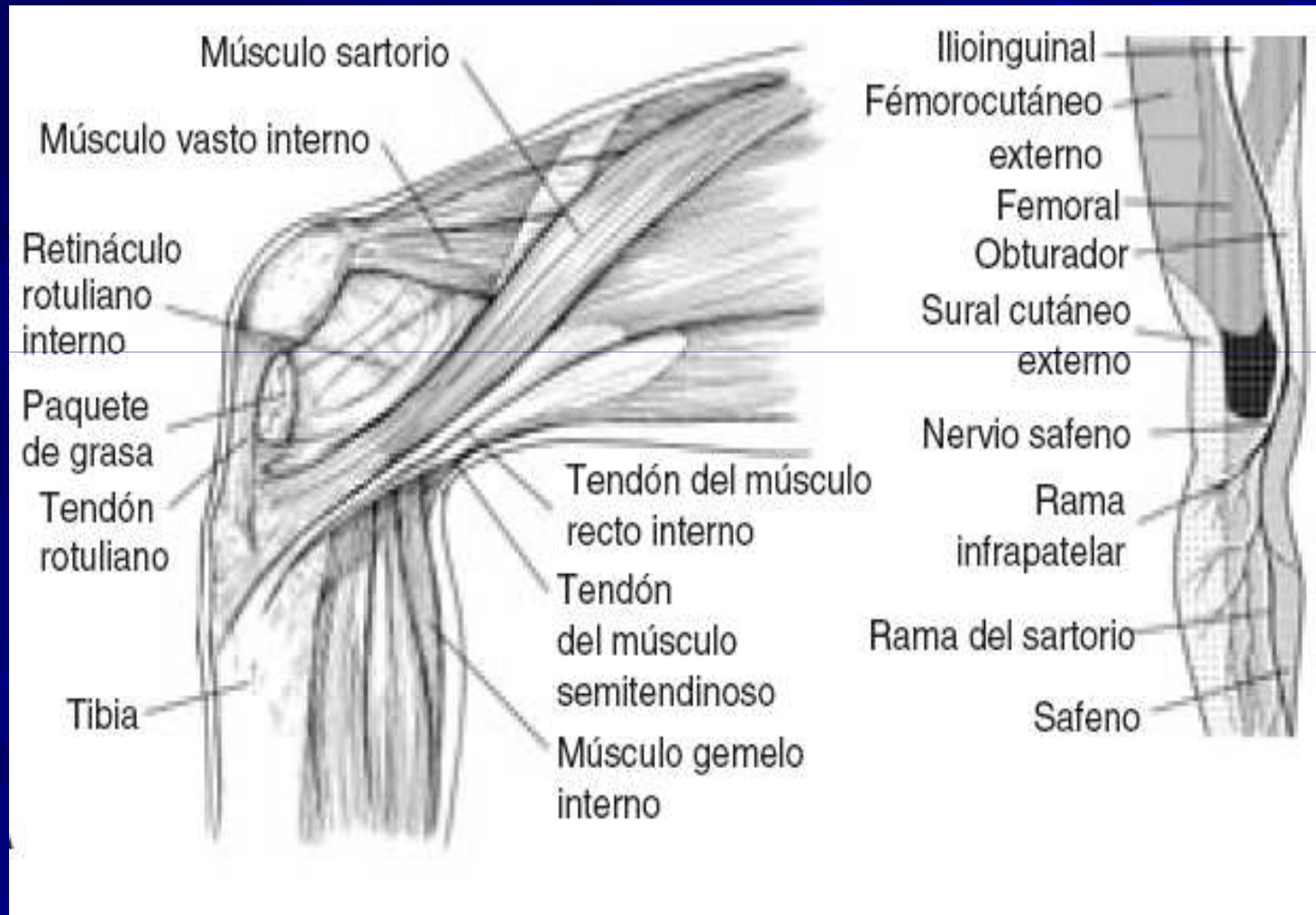
ANATOMIA

Knee Medial View



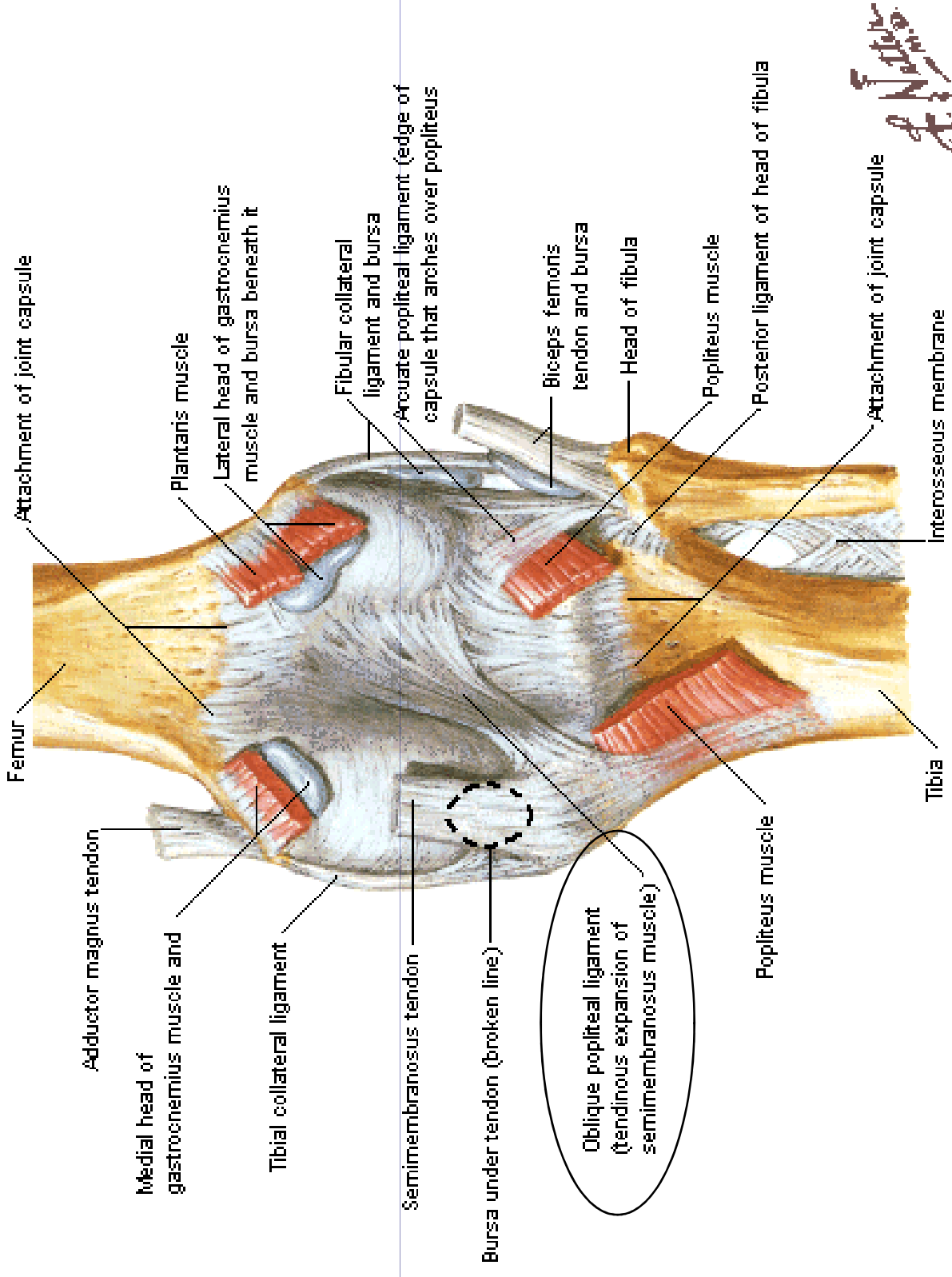
F. Natter
M.D.

ANATOMIA



Knee

Posterior View

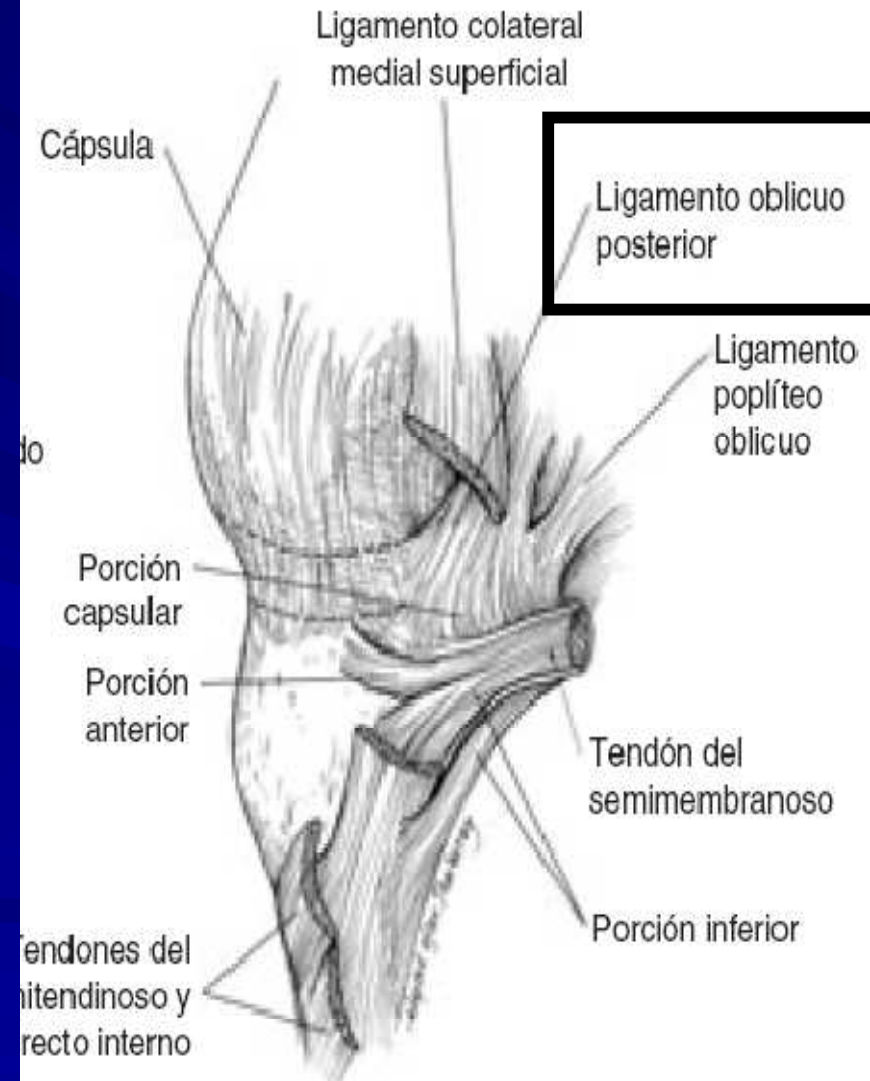


F. Netter M.D.
© 2004 Elsevier

CPM

ESTATICOS

- LCM superficial
- Ligamento capsular medio LCM profundo
- Ligamento obliquo posterior



CPM

DINAMICOS

- Tendao semimembranoso
- Tendoes pata ganso
- Cabeça medial gastrocnemio

CPL

- Controle do varo, translacao posterior e rotacao externa

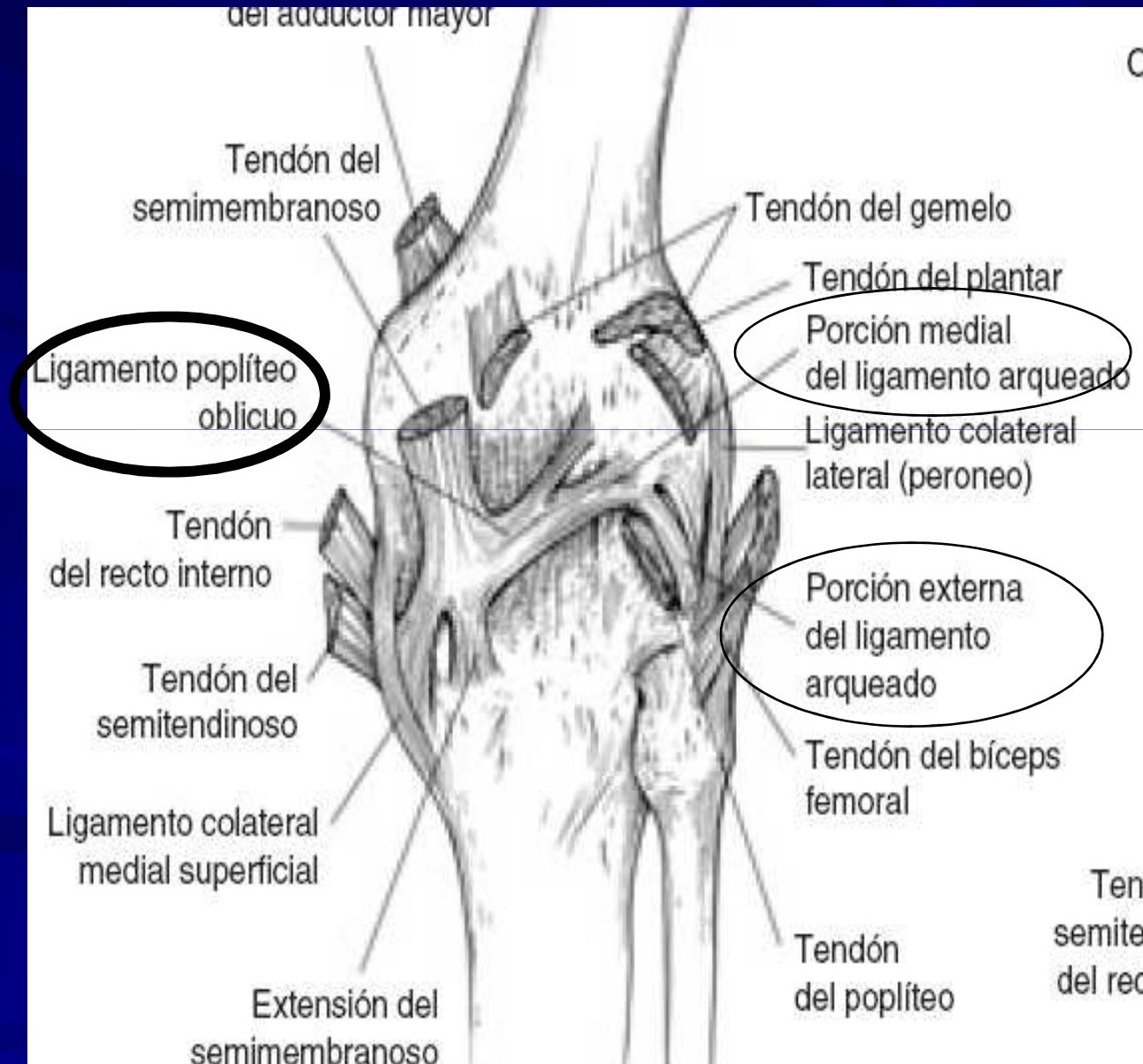ESTATICOS

- LCL
- Trato iliotibial
- Complexo arqueado

CPL

- COMPLEXO ARQUEADO
- Confluencia de varias estruturas
- Porcao lateral(externa) do lig. arqueado= lig. Fabelofibular
- Porcao medial do lig. arqueado= lig. Popliteo obliquo
- Lig. Aqueado = Y invertido
- Fabela X Tendao m. popliteo

CPL



CPL

DINAMICOS

- Tendao popliteo (musculo)
- Cabeca lateral gastrocnemio
- Biceps femural

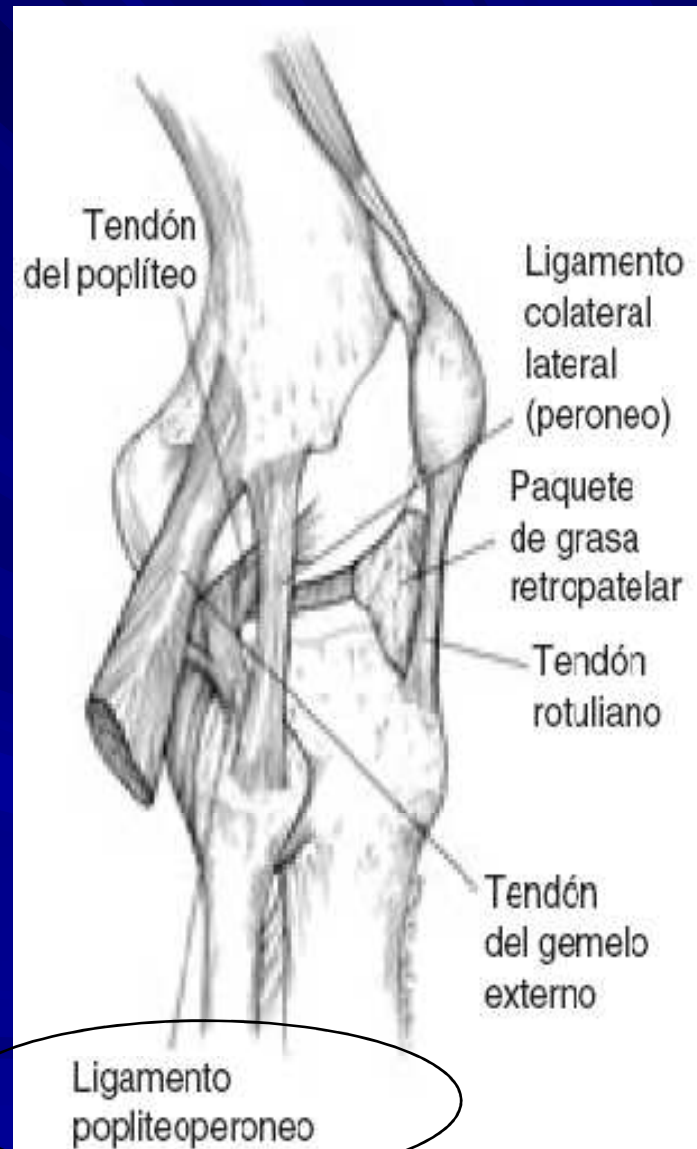
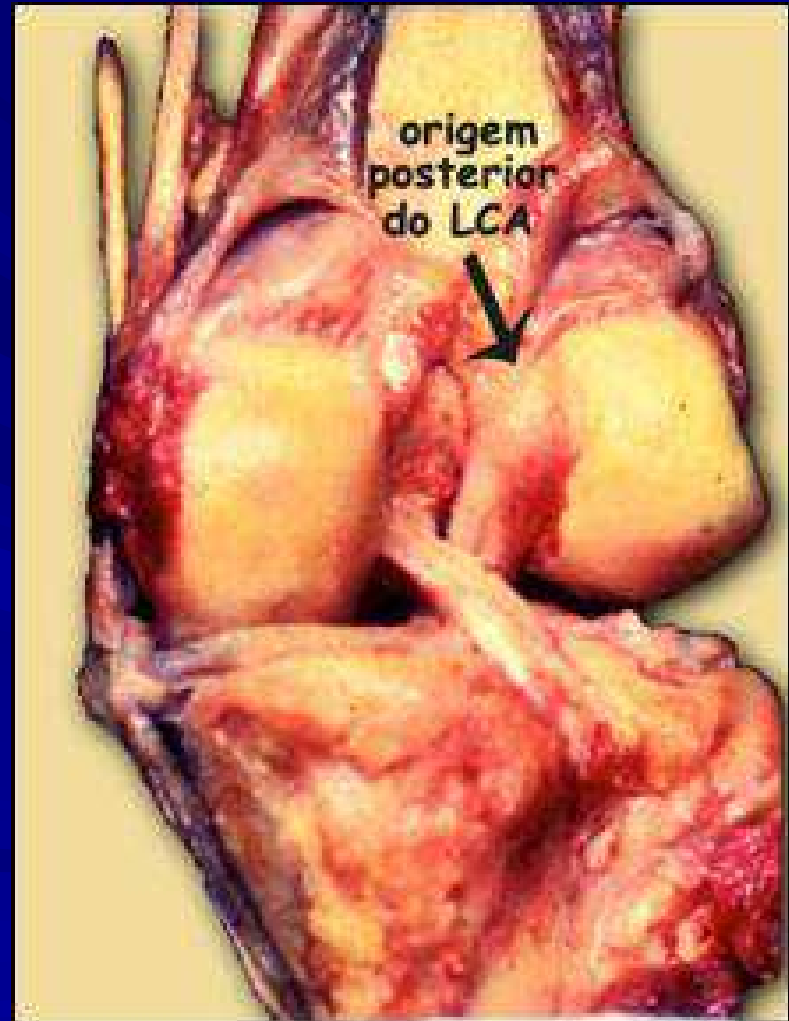
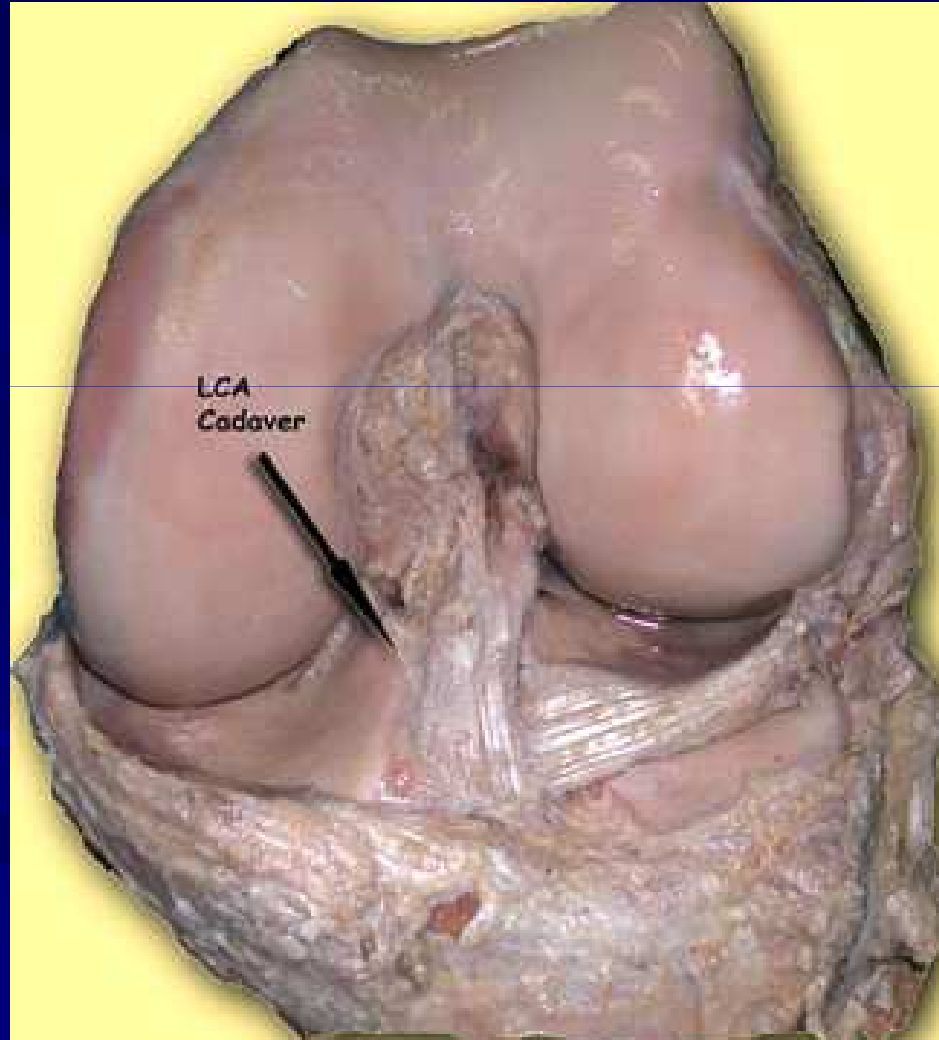


Figura 4. Complejo anatómico posteroexterno.

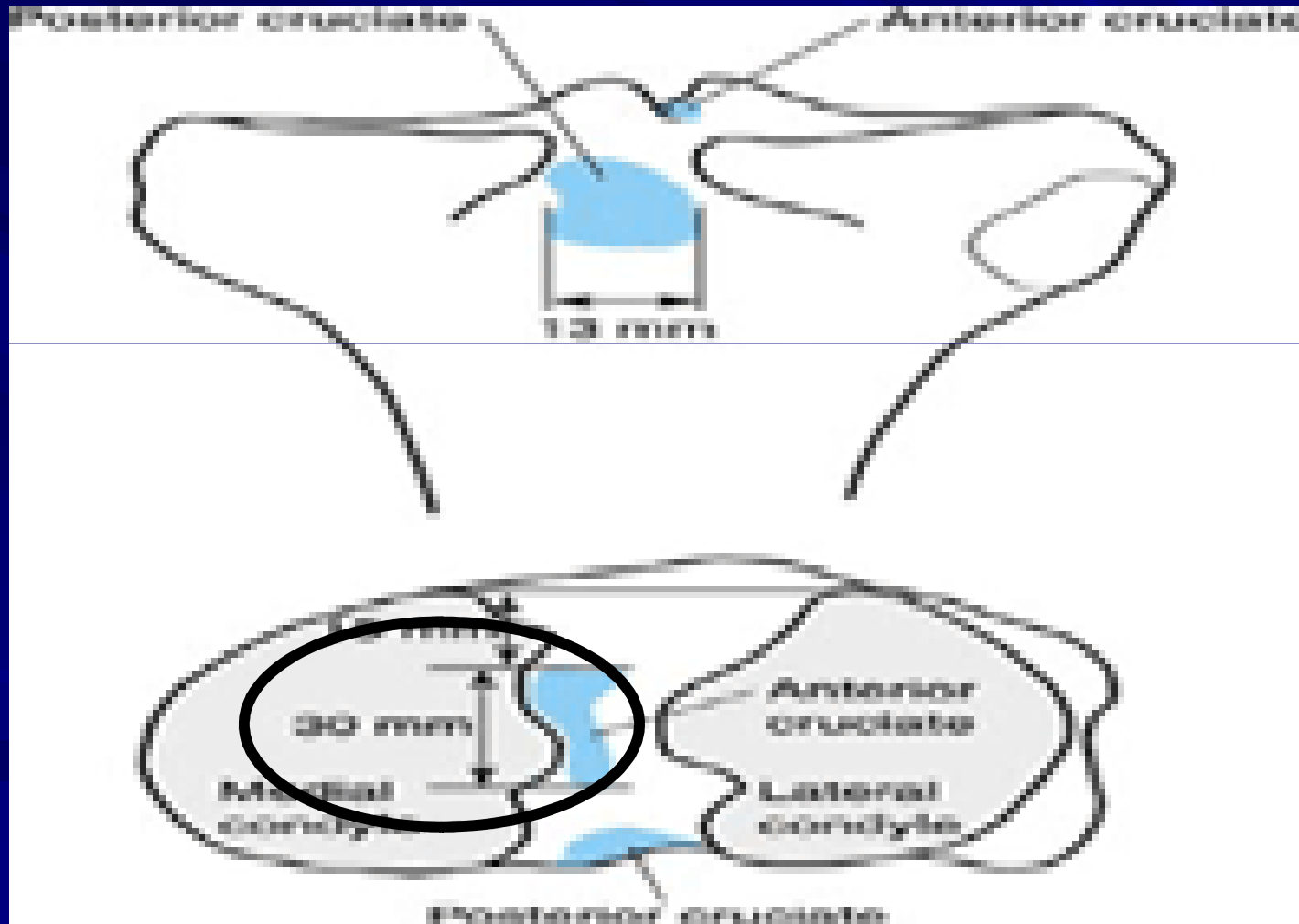
LCA

- Intra-articular, extra-sinovial
- Comprimento de 38mm e largura 11mm
- Origem: face póstero-medial do intercôndilo femoral lateral, semicírculo, 2 cm
- Inserção: em leque (30mm), ântero-lateral à espinha tibial anterior, relação com corno anterior dos meniscos

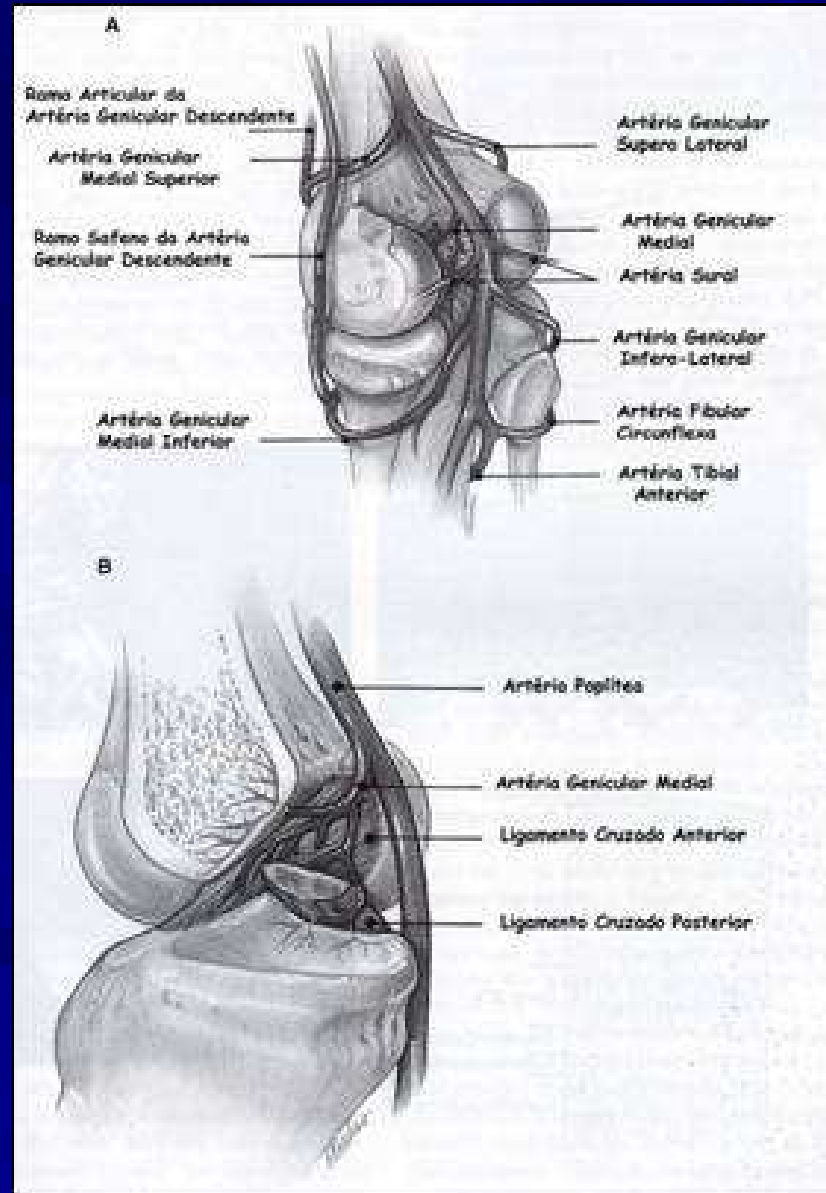
LCA



LCA

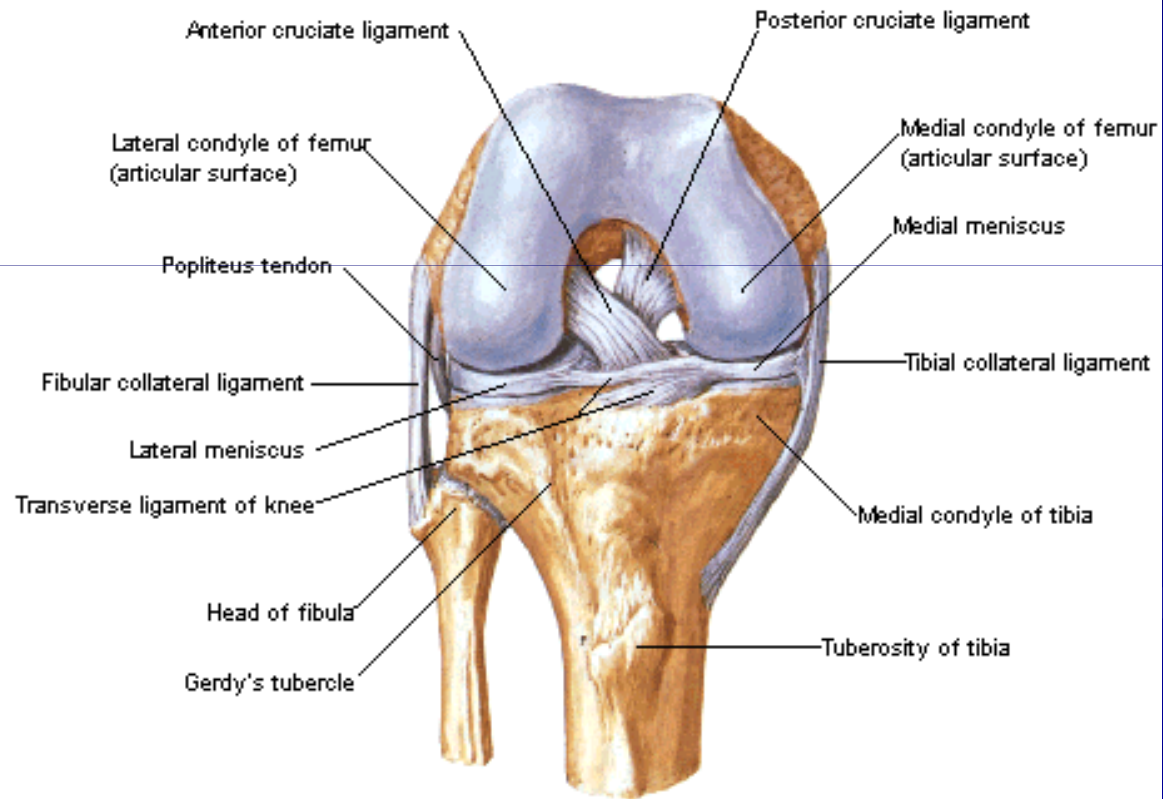


ANATOMIA



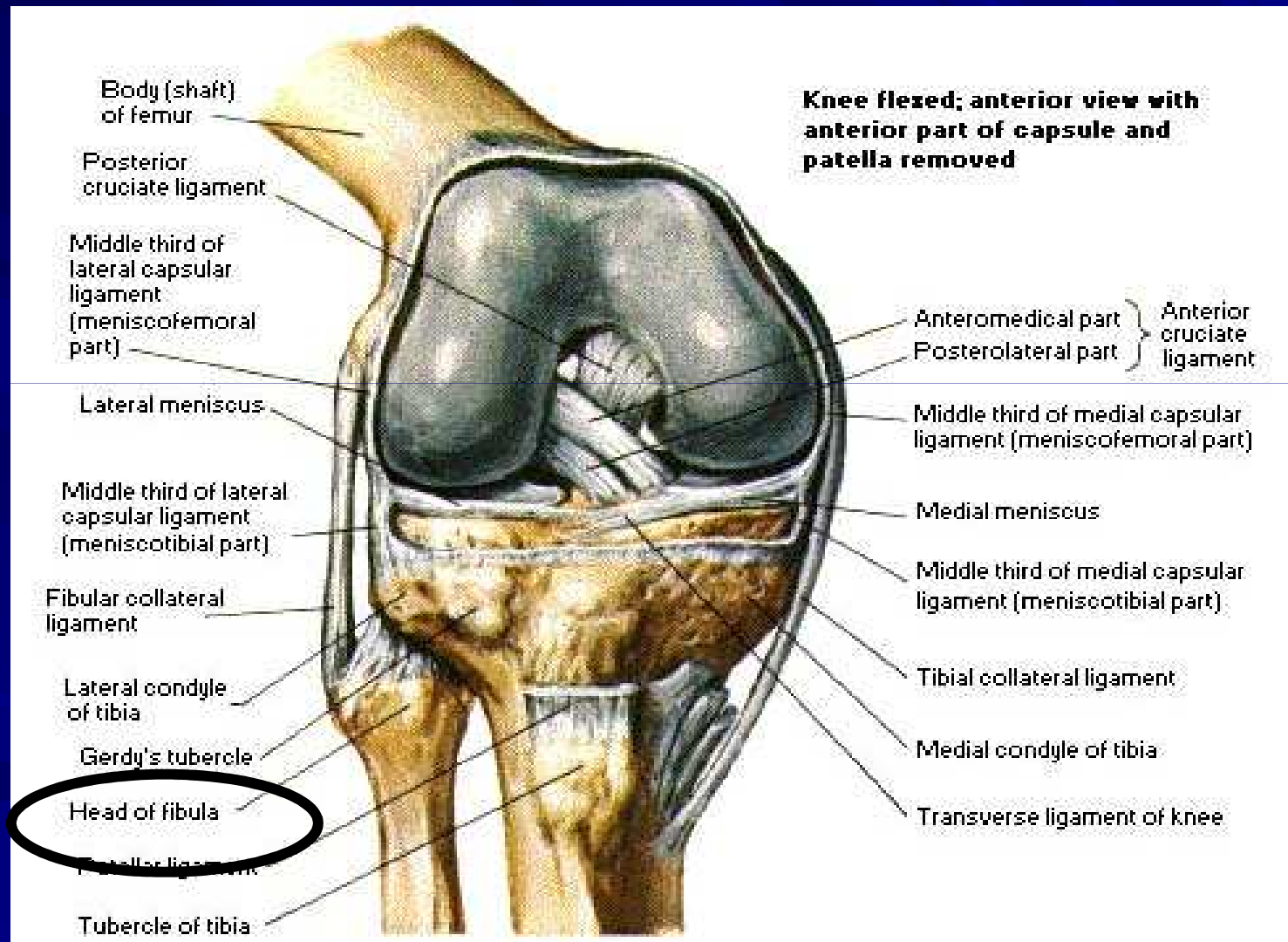
ANATOMIA

Knee - Cruciate and Collateral Ligaments Right Knee in Flexion



Anterior View

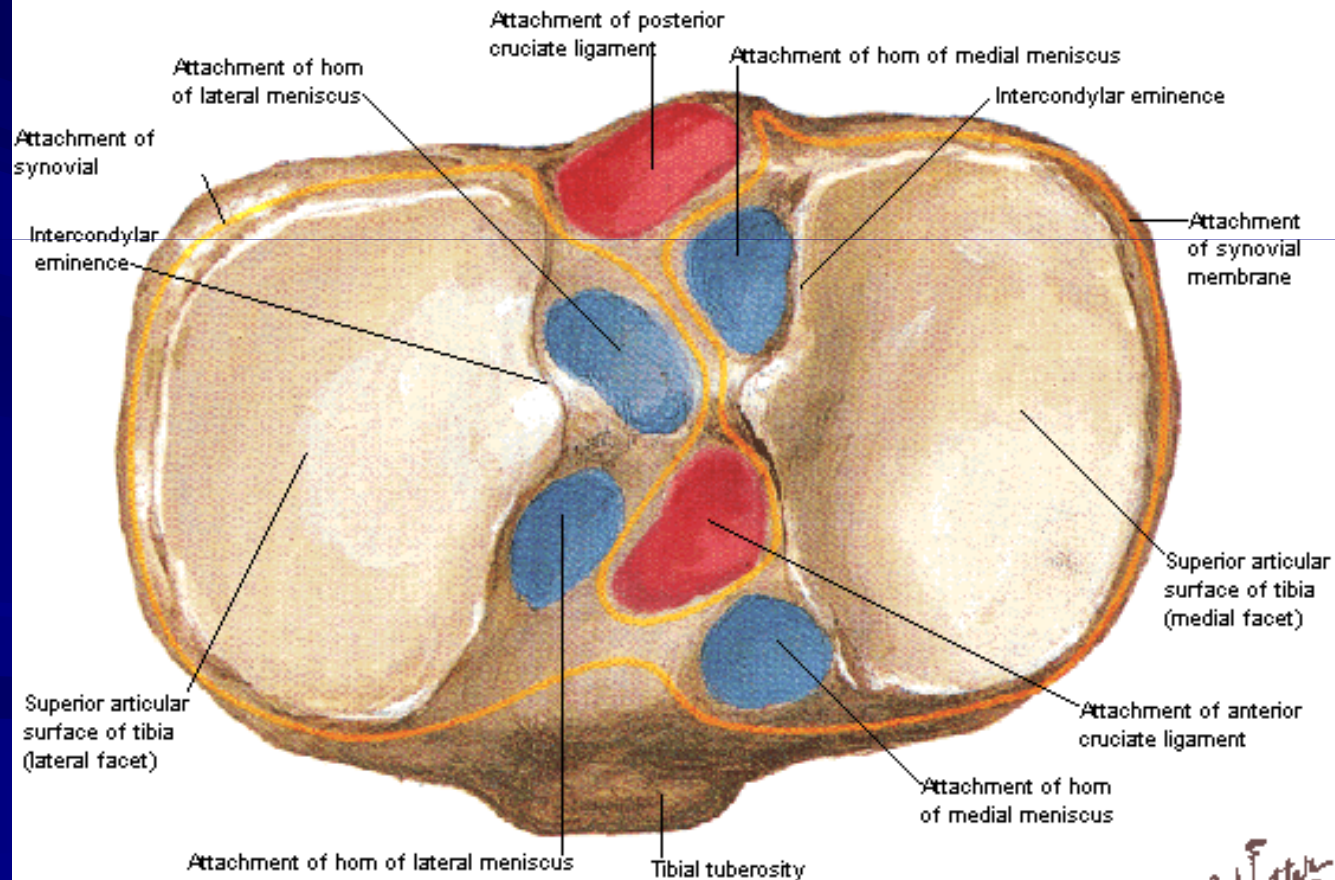
ANATOMIA



ANATOMIA

Knee - Interior

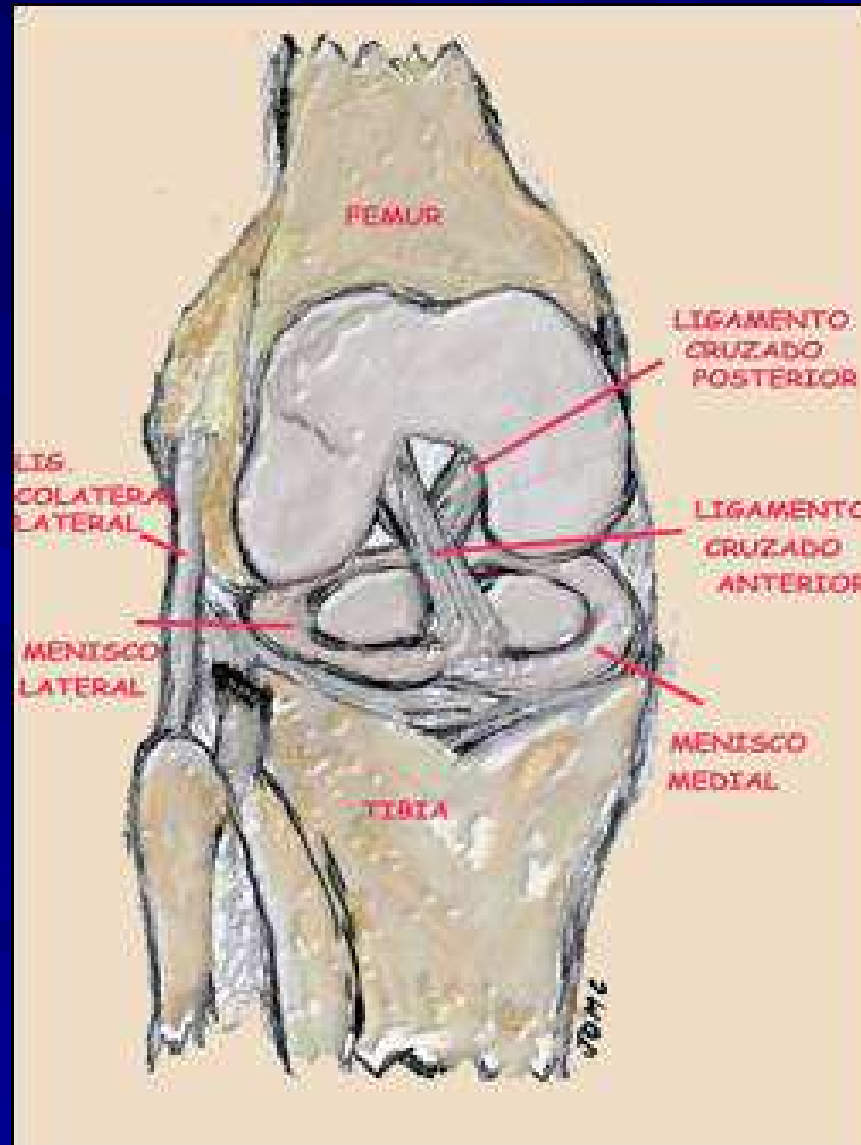
Superior View, Ligaments and Cartilage Removed



F. J. Netter
M.D.
© CIBA-GEIGY

ANATOMIA

■ Hipocrates



LCP

- 2 feixes: ântero-lateral(tenso em 90°)
pósterio-medial(tenso em
extensão)

Feixe ântero-lateral mais resistente(1.669N)

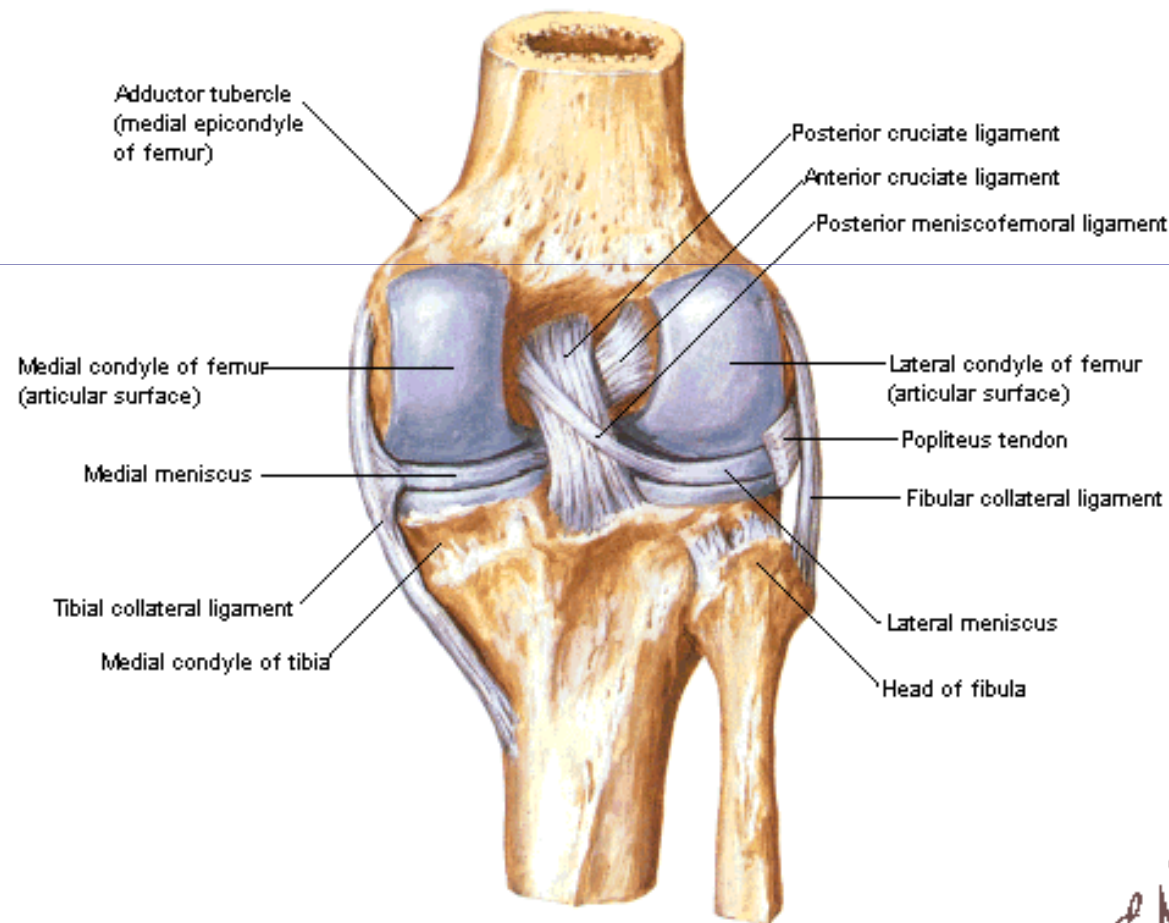
Feixe pósterio-medial (450N)

- Ligamentos meniscofemorais: Humphrey
e Wrisberg 20% da estabilidade

LCP

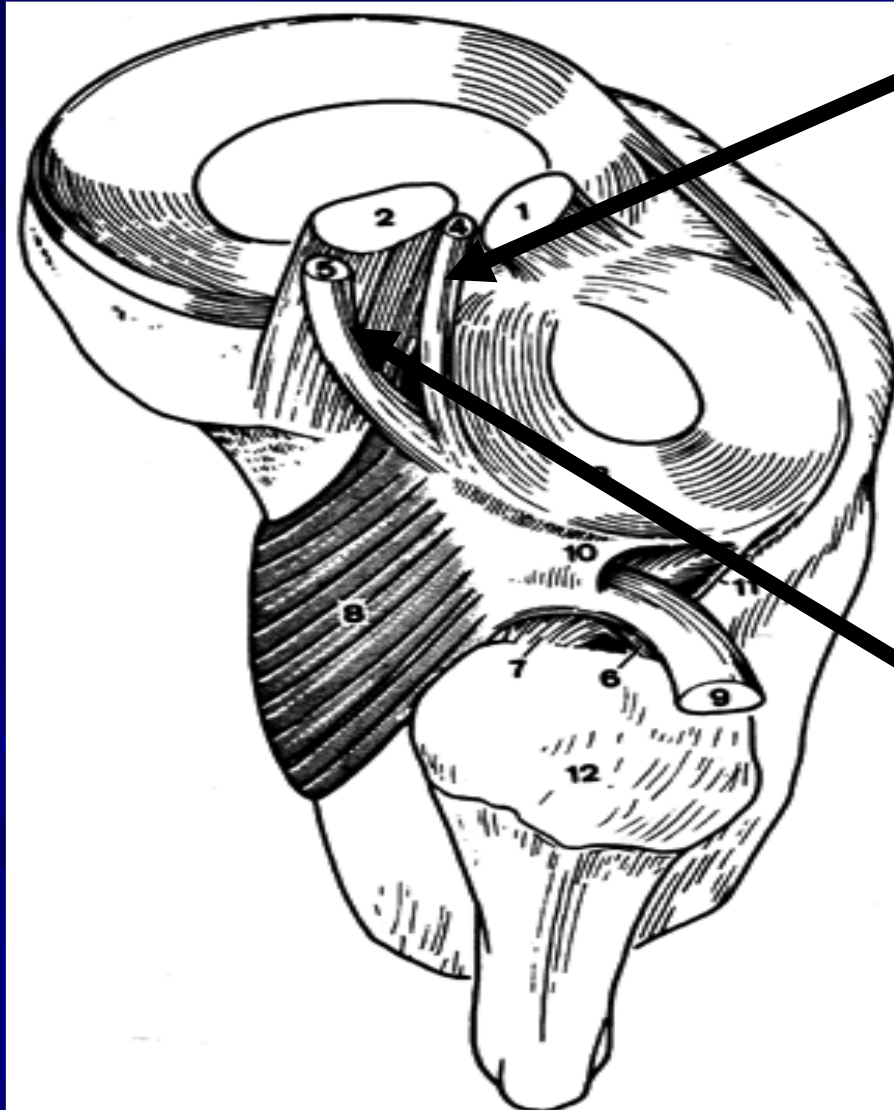
Knee - Cruciate and Collateral Ligaments

Right Knee in Extension



Posterior View

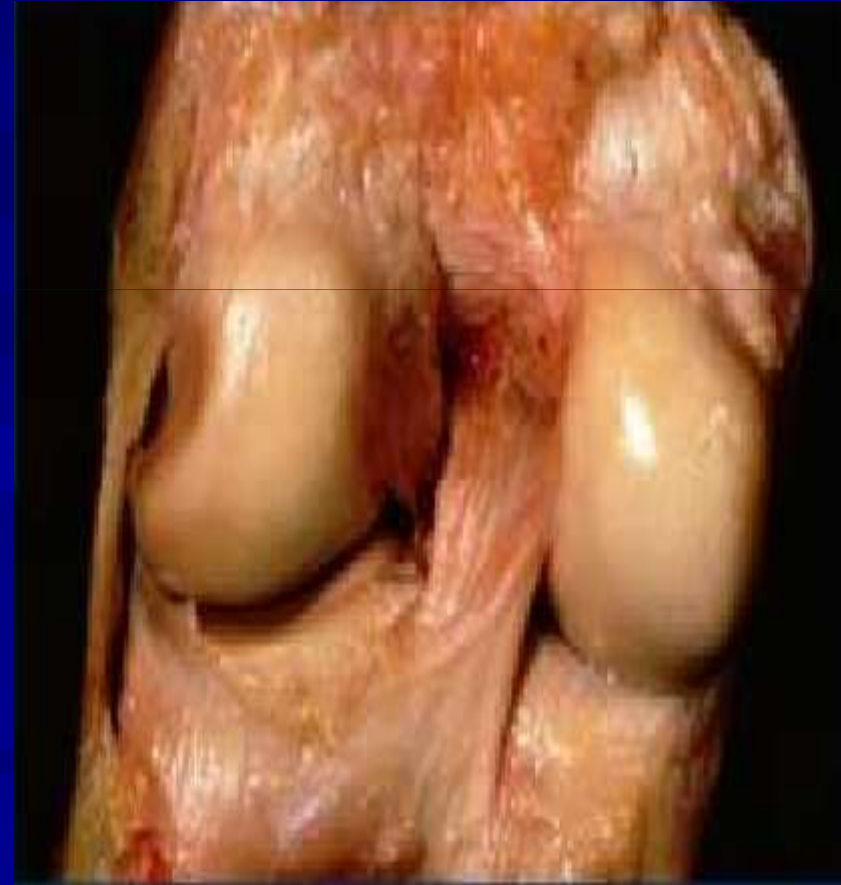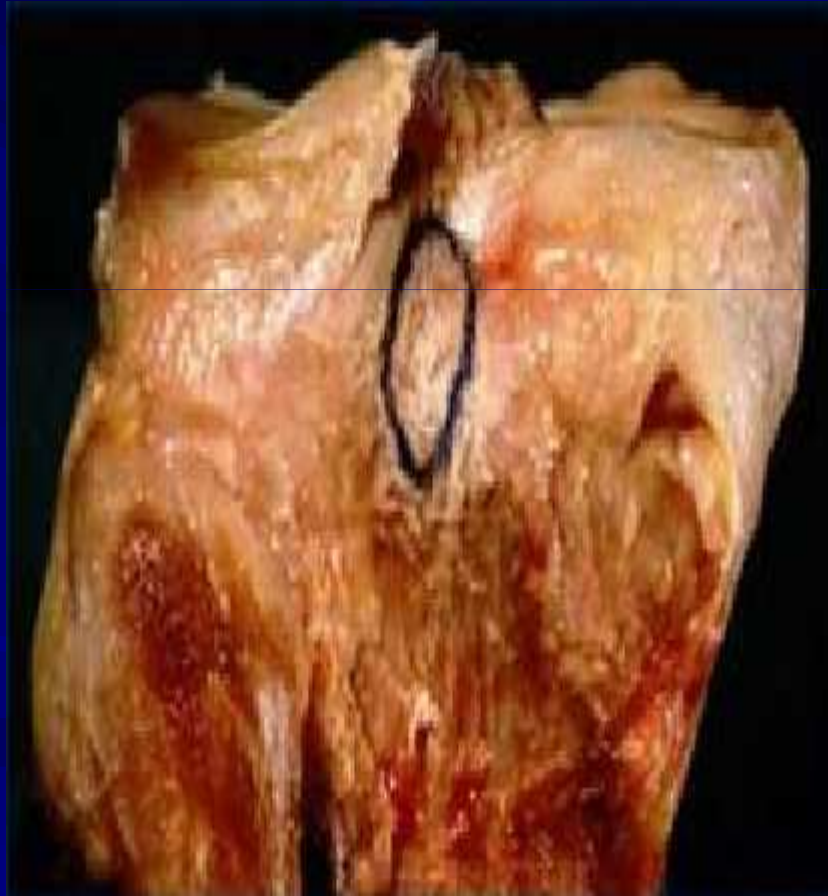
ANATOMIA



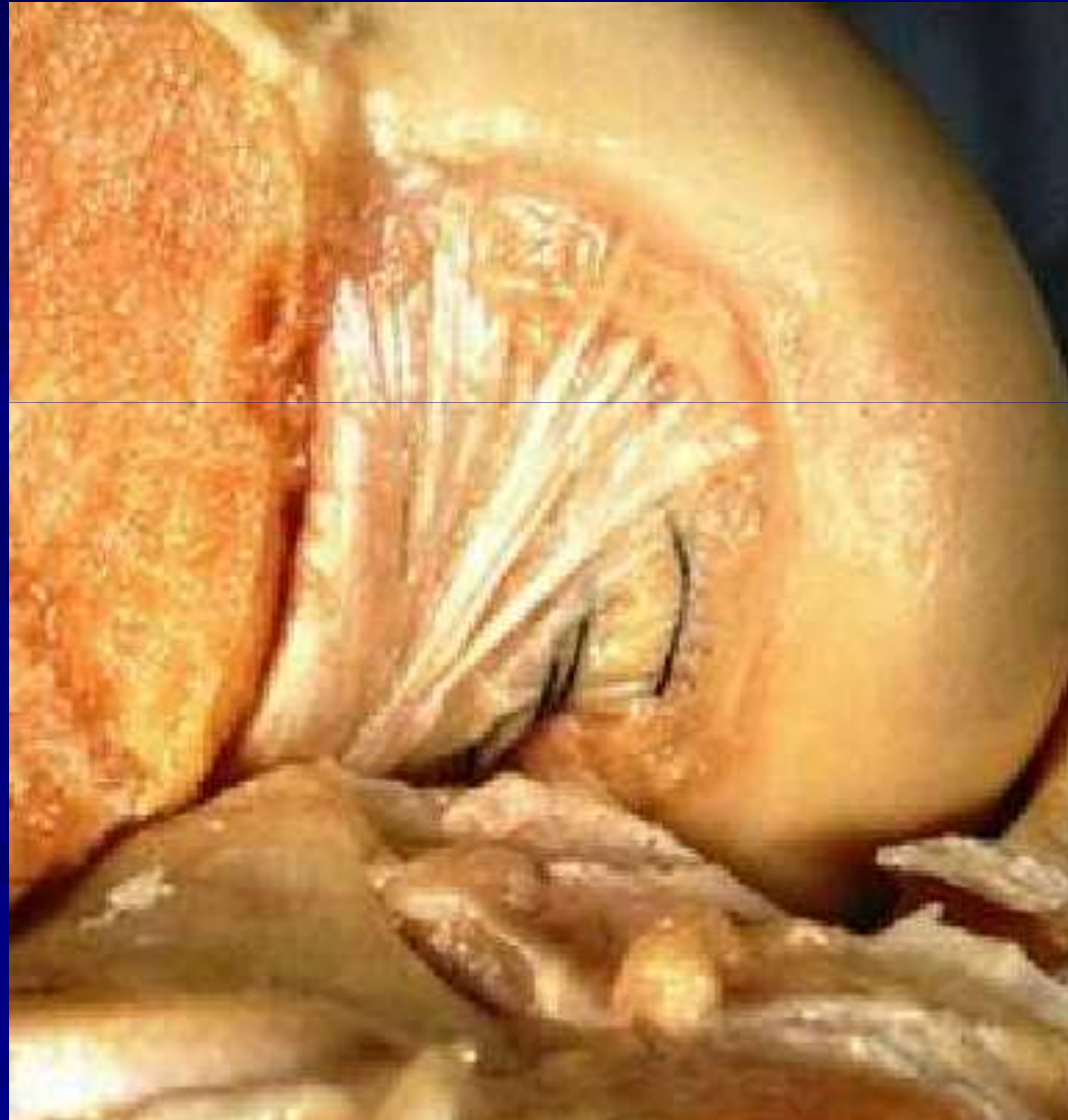■ Ligamento Humphrey

■ Ligamento Wisberg

LCP = 1,5/ 2,0 CM

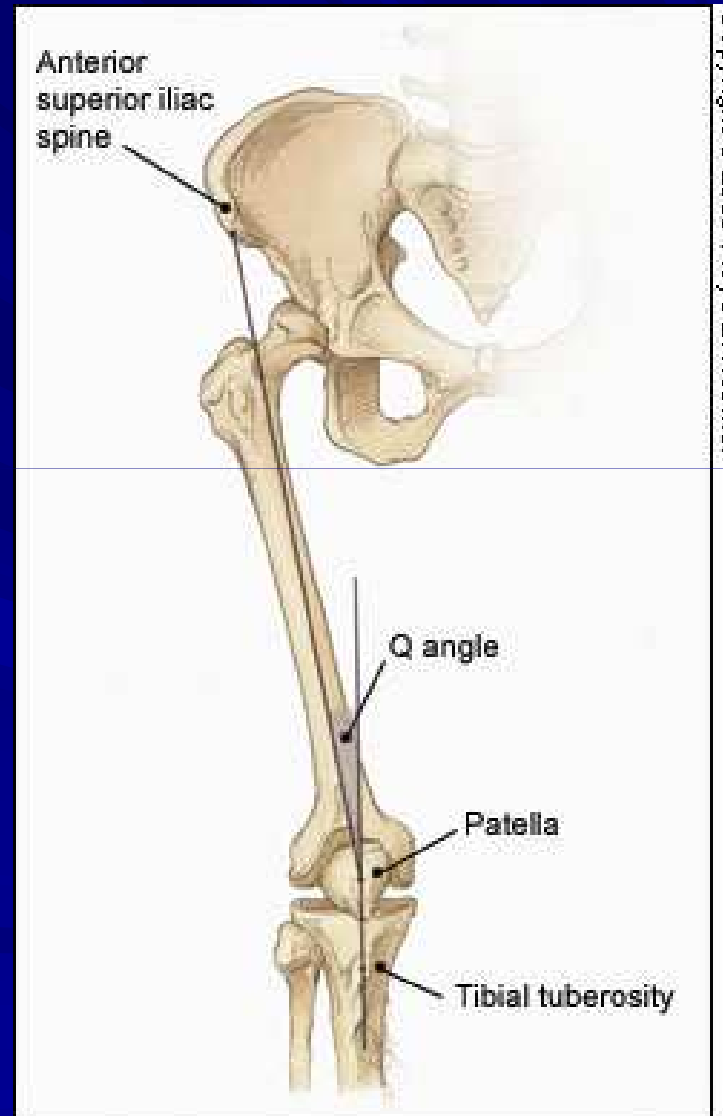


1 Banda=10-11 mm

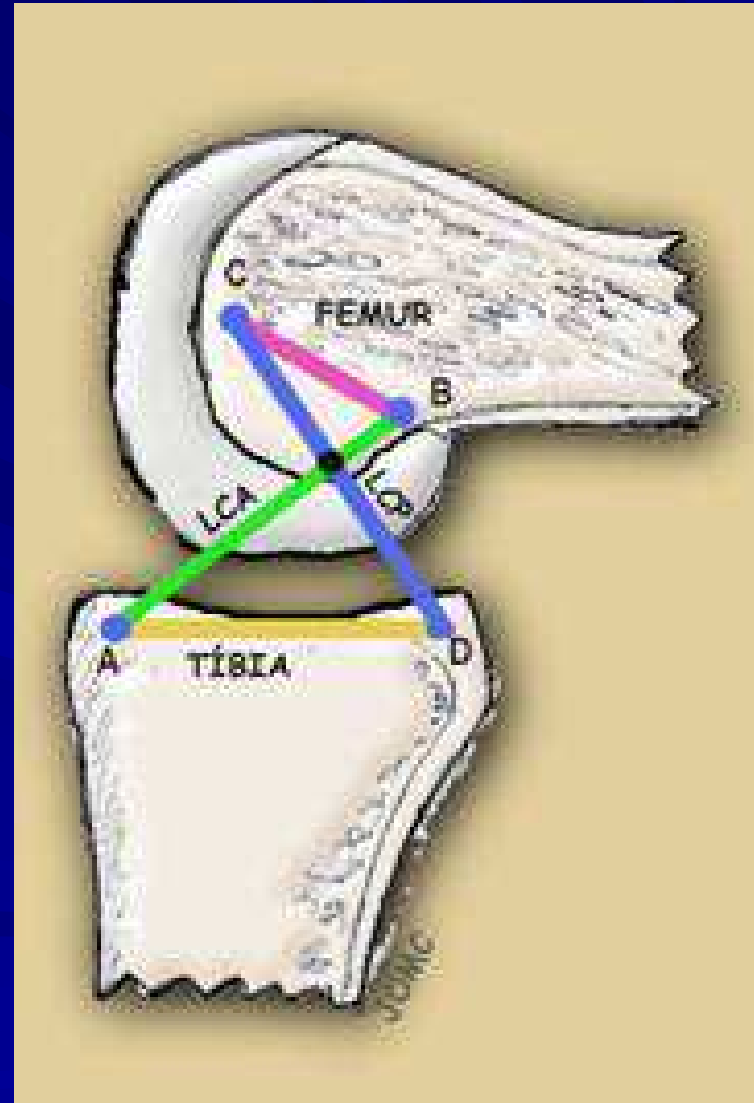
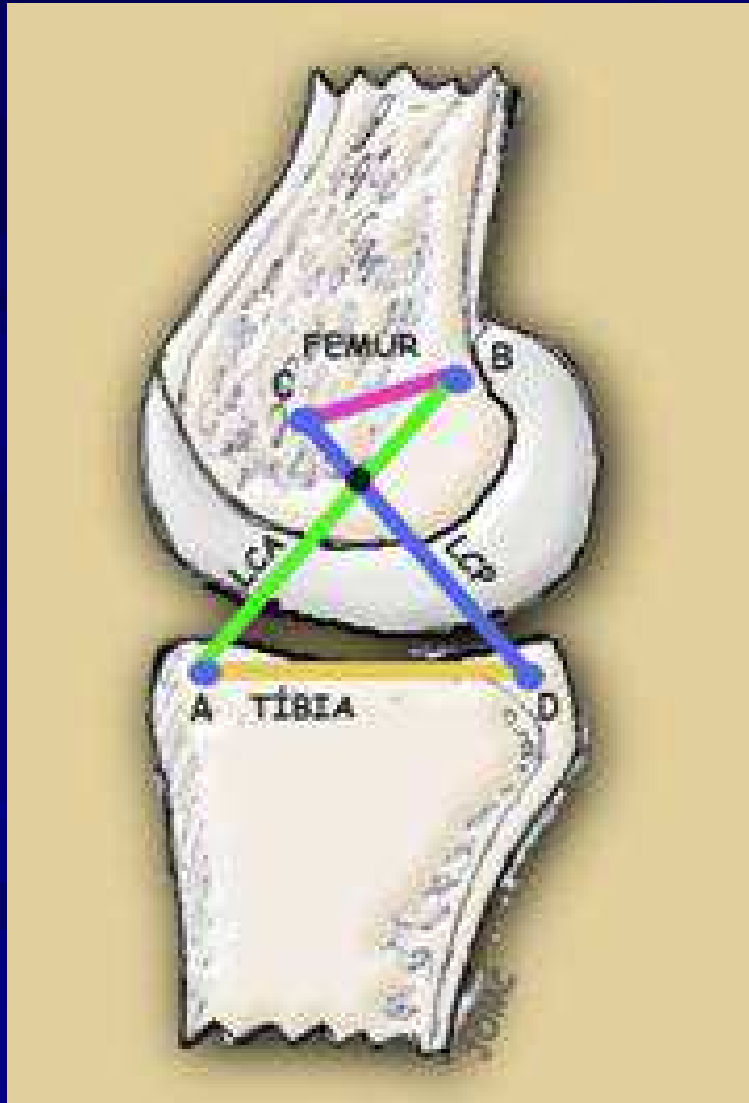


BIOMECHANICA

- ANGULO Q
<20 GRAUS



BIOMECHANICA



BIOMECANICA-LCA

- Resistencia = 2.160 N
- Duas porções:
 - ântero-medial: flexão
 - póstero-lateral: flexão e extensão, mais espesso (ISOMETRICO)

BIOMECANICA-LCP

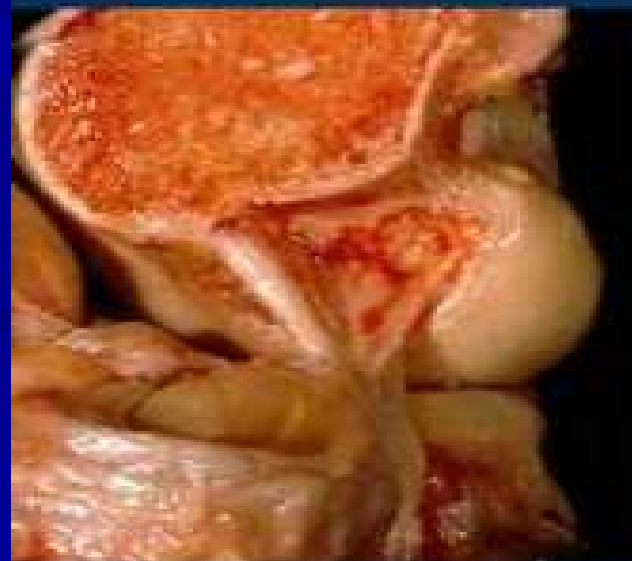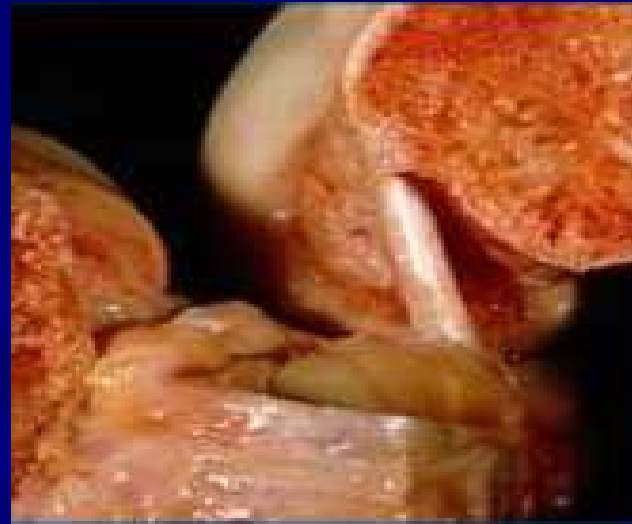- Feixe ântero-lateral mais resistente(1.669N)- ISOMETRICO

Feixe póstero-medial (450N)

- Ligamentos meniscofemorais: Humphrey e Wrisberg 20% da estabilidade

BIOMECANICA-LCP

- Banda anterolateral
tensa em flexão
(1600 N)
- Banda póstero-medial
tensa em extensão
(445 N)



SEMIOLOGIA-LIGAMENTAR

- Lachmann
- Gaveta anterior/posterior
- Stress varo/valgo
- Lateral pivot shift
- Jerk test
- Godfrey
- Rotacao externa 30 e 90 graus

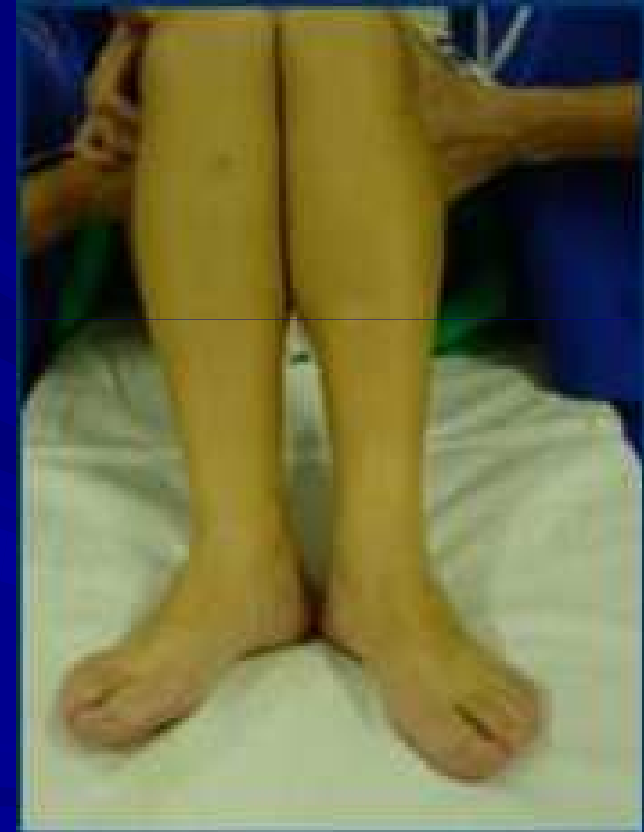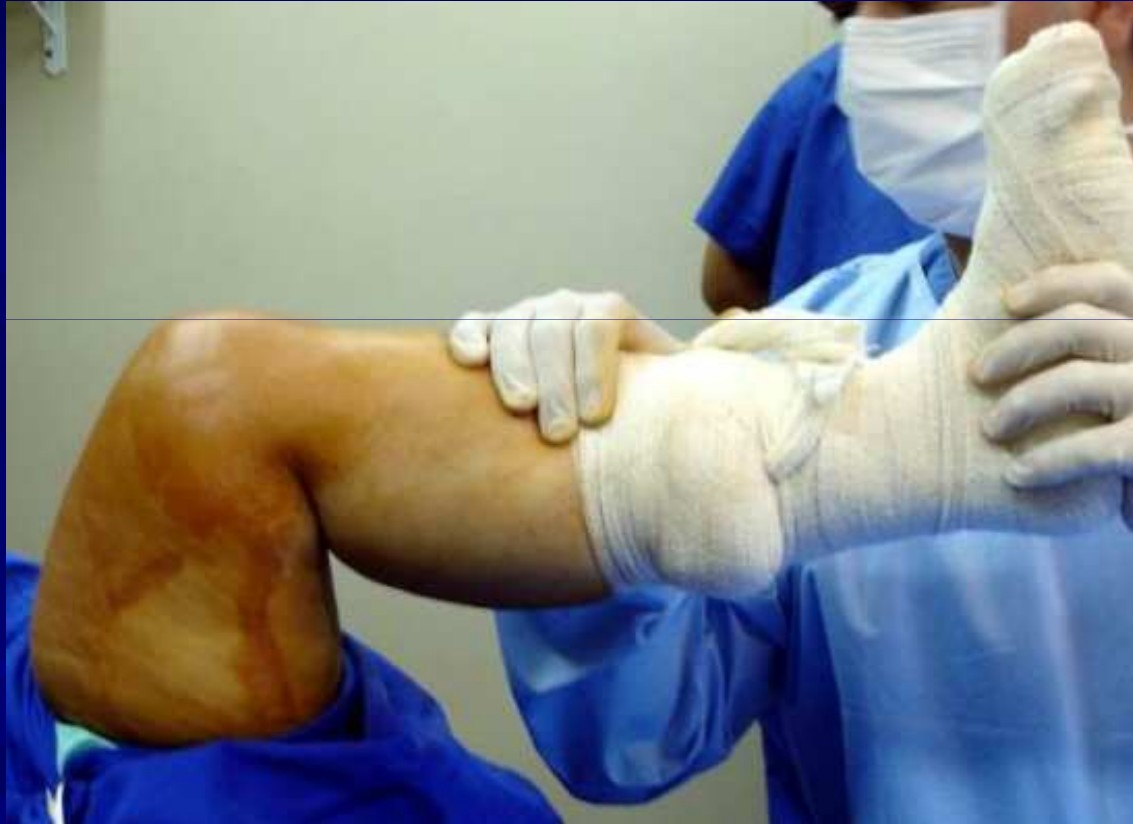SEMIOLOGIA-MENISCAL

- McMurray
- Appley
- Steinmann

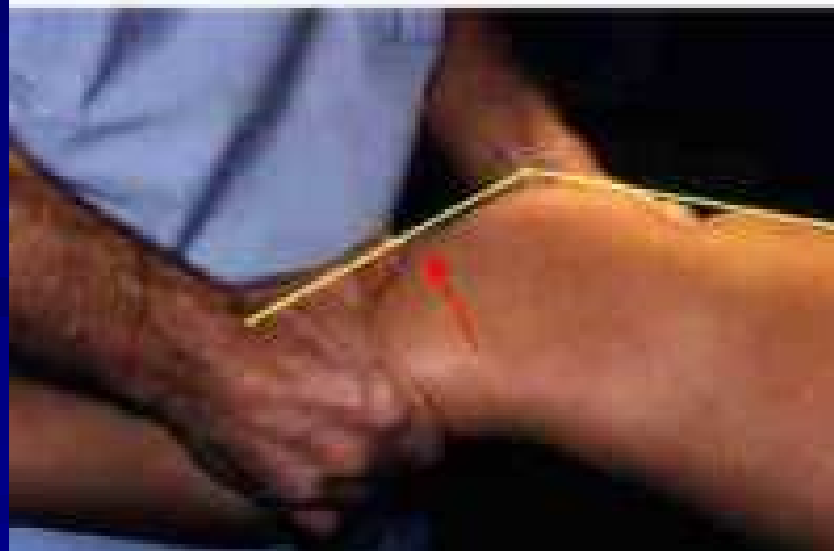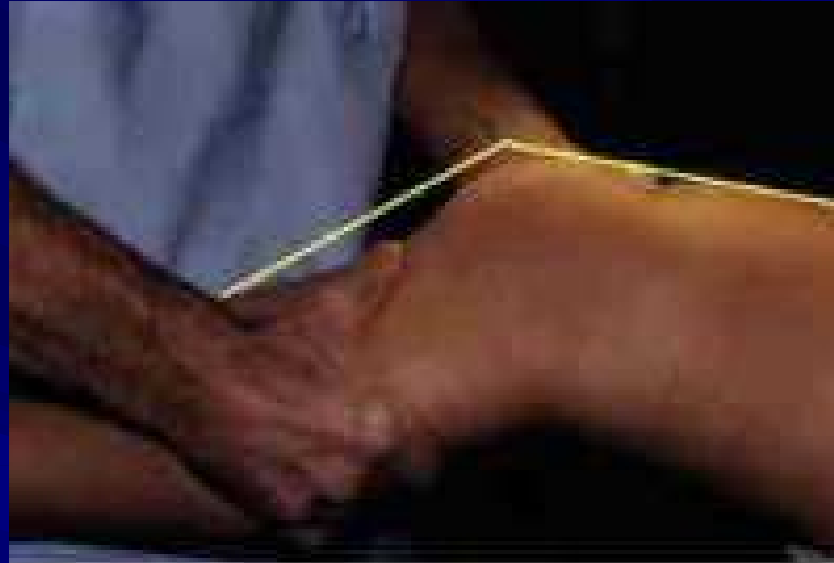SEMIOLOGIA-PATELA

- Sinal pedra gelo
- Sinal de Smillie
- Rabot
- Zollen

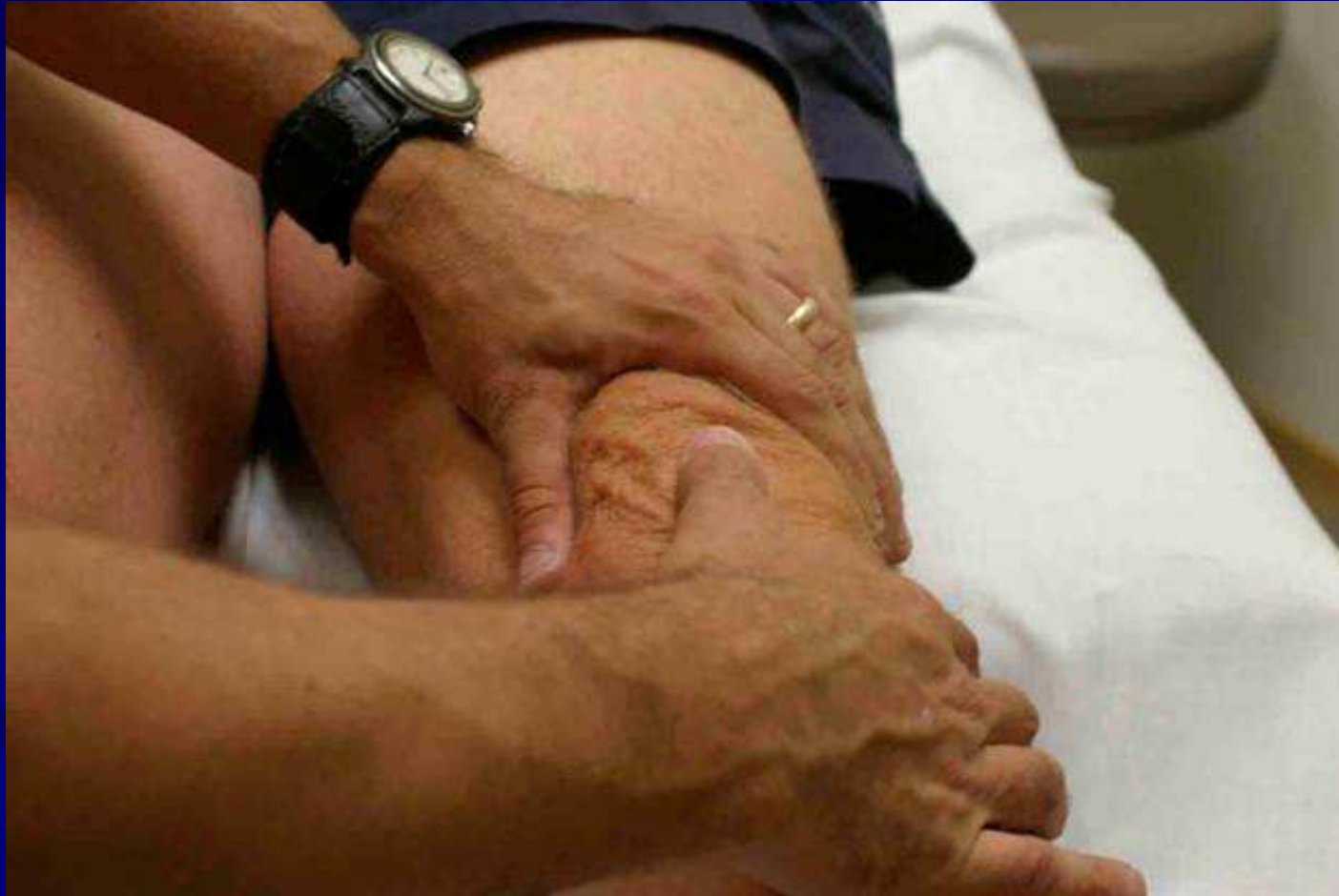SEMIOLOGIA



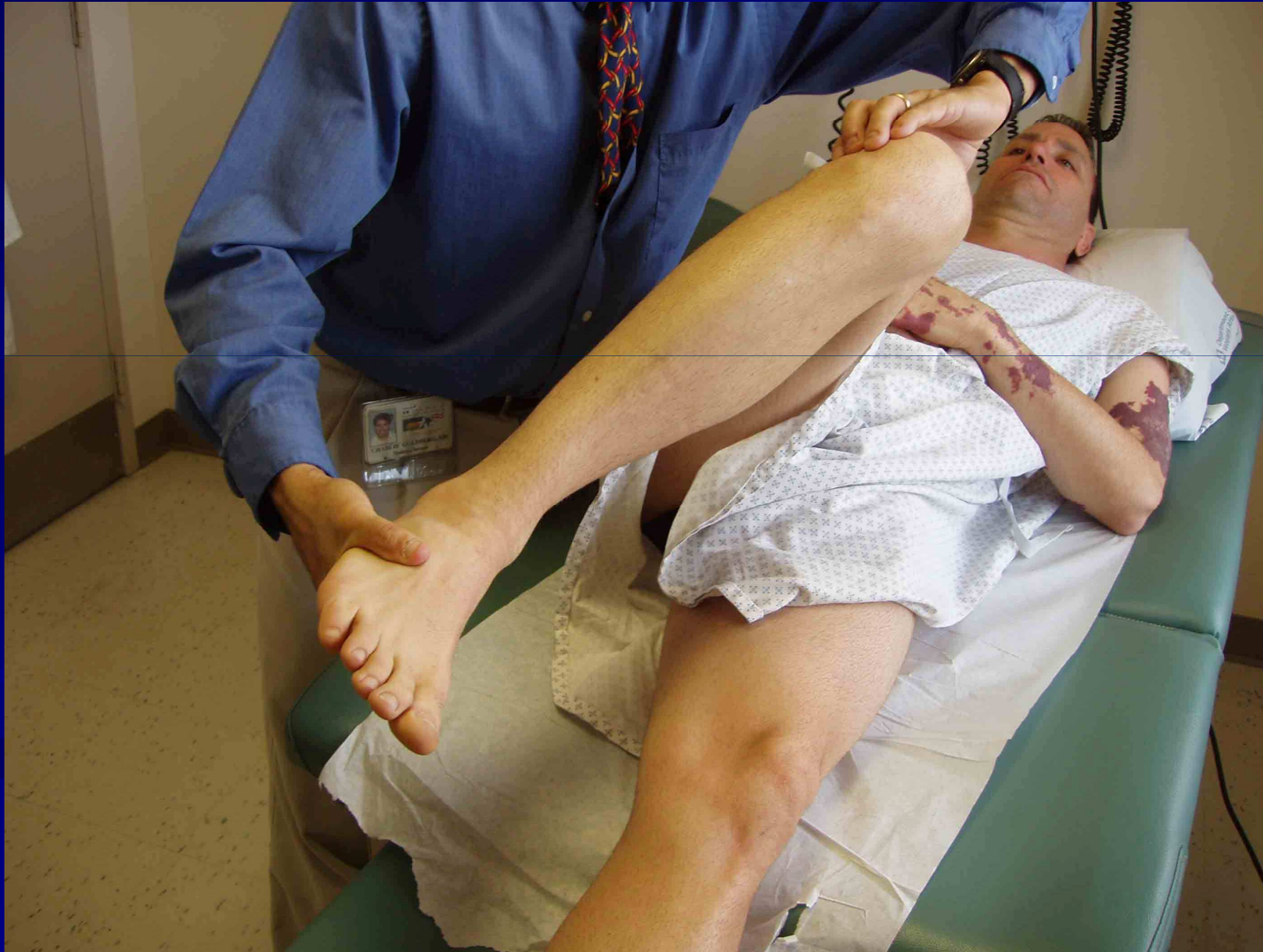SEMIOLOGIA



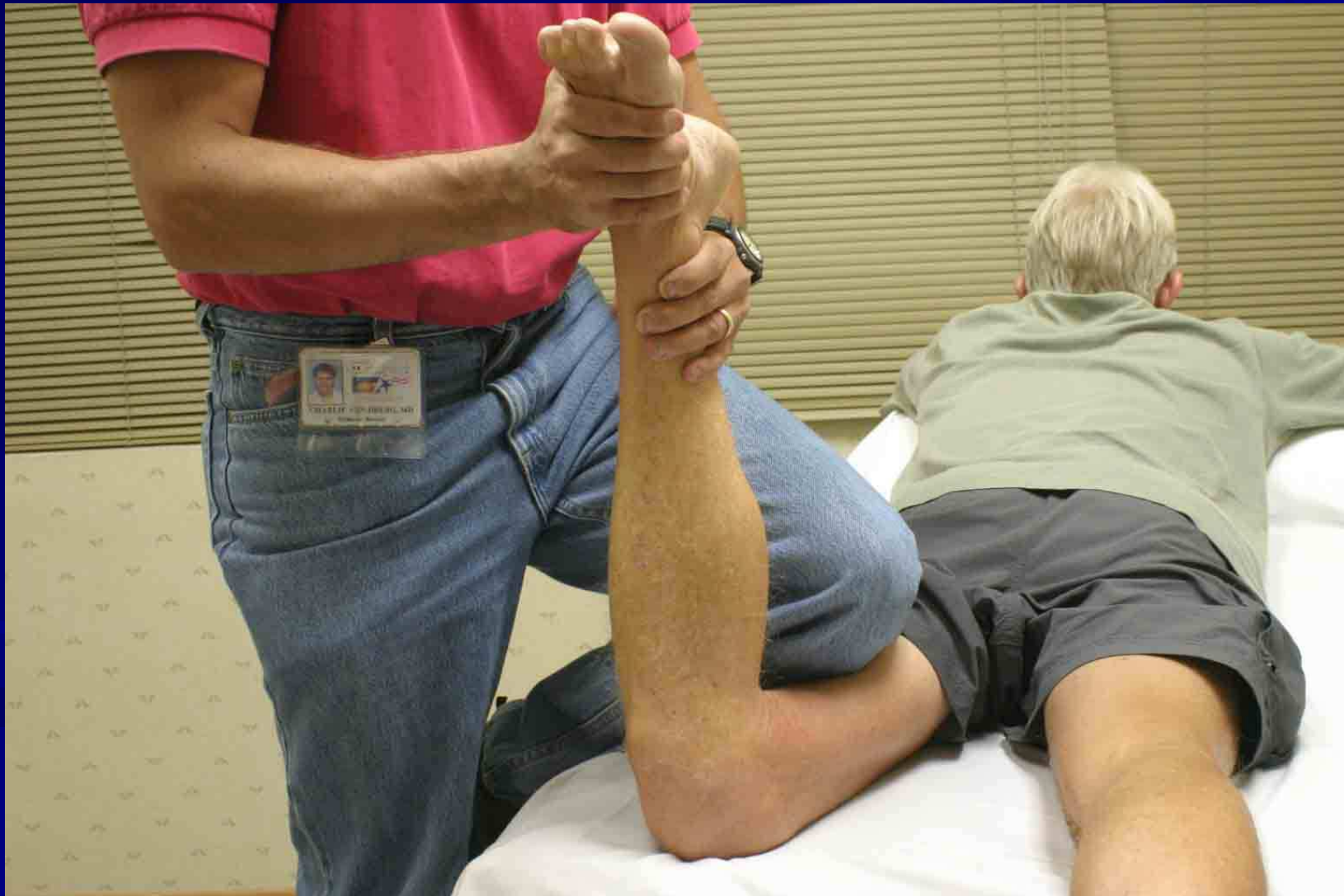SEMIOLOGIA



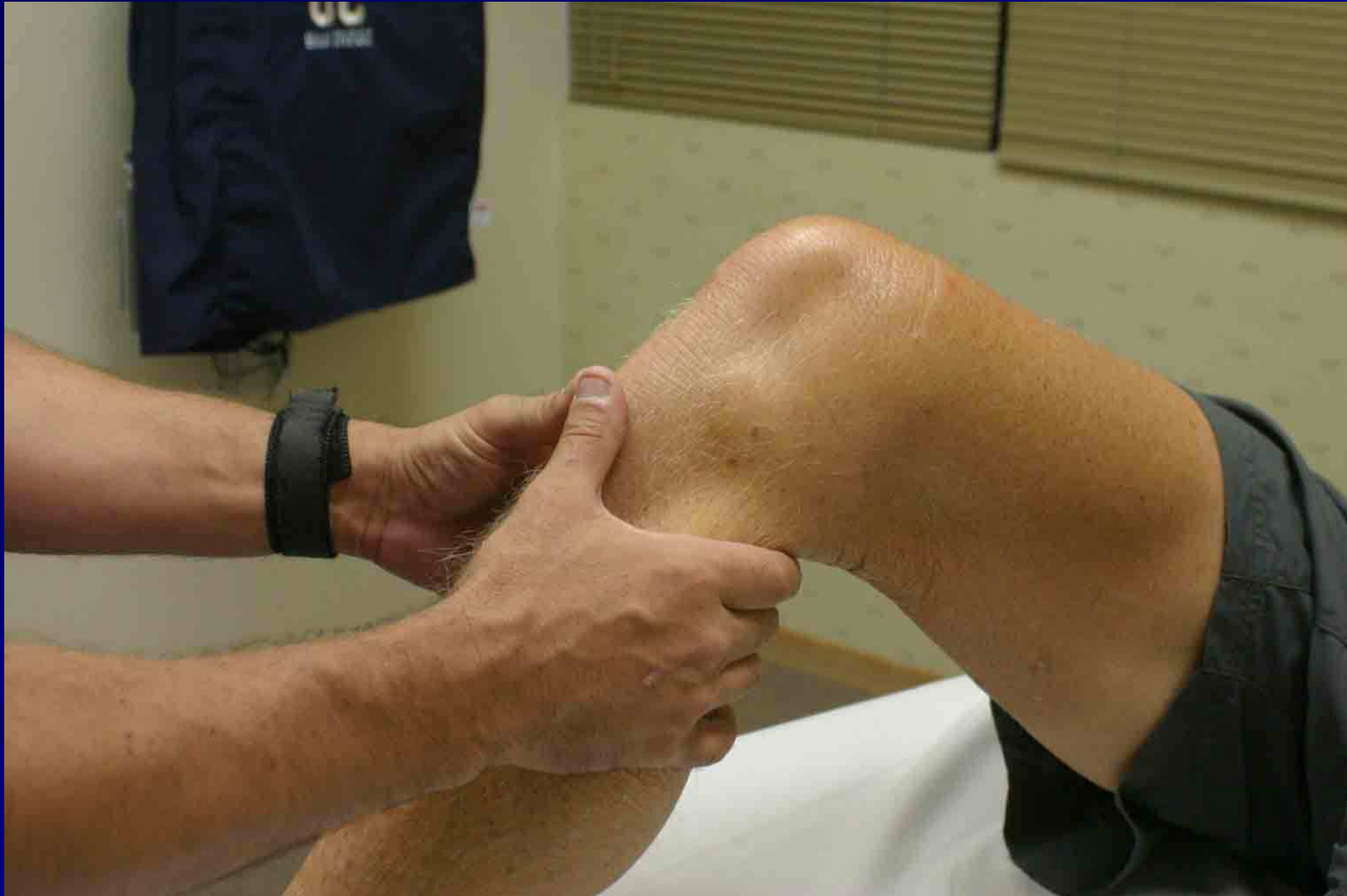SEMIOLOGIA



SEMILOGIA



SEMIOLOGIA



SEMIOLOGIA



SEMIOLOGIA

